

The Efficiency of an X-Ray Screening System at a Mass Disaster*

REFERENCE: Goodman NR, Edelson LB. The efficiency of an X-ray screening system at a mass disaster. *J Forensic Sci* 2002; 47(1):127-130.

ABSTRACT: This is a study to determine the efficiency and efficacy of using an X-ray security screening system to locate both dental fragments and other foreign objects that might be commingled with fragmented remains in a mass disaster.

A controlled study by the Pennsylvania Dental Identification Team (PADIT) revealed that a manual examination of simulated body bags containing commingled dental parts and foreign objects by a team of trained forensic odontologists was very effective in locating dental fragments and in finding foreign objects.

Although this was effective, it was not efficient, because it was very time consuming. With the use of an X-ray security screening system, the time factor could be reduced. This study also revealed that even though this sophisticated equipment could reduce the time factor in locating commingled dental and foreign objects, a forensic odontologist should be utilized to be most effective.

KEYWORDS: forensic science, forensic odontology, fragmented and commingled remains, X-ray security screening system

At a mass disaster site, the search and recovery teams must collect, mark, and record all materials suspected to be part of the disaster; this would include bodies, body parts, personal possessions, cargo, and parts of the vehicle. These objects, which may be commingled, are placed in body bags and taken to a temporary morgue near the disaster site or transported directly to the permanent morgue. After transportation, an accurate and prompt identification of each victim is desired.

In the U.S. Air Flight 427 crash near Pittsburgh, Pennsylvania, on 8 Sept. 1994, there were 133 passengers and crew who were casualties of this disaster. Over 1500 body bags were collected containing fragmented and commingled remains of victims to be evaluated. A temporary morgue was set up in a hanger at Pittsburgh International Airport. A portable X-ray unit was brought in, and X-rays of the body bags were taken on site. After initial examination, the body bags were then immediately placed into refrigerator trucks.

However, the X-ray plates had to be transported to a nearby hospital to be processed. The average turnaround time for a particular batch of film was approximately 3 h. This delay presented some problems. In several cases, dental fragments were noted on the X-

ray that may have been overlooked during the initial manual search and retrieval process. These bags then had to be retrieved from the refrigerated trucks and manually searched, and then dental X-rays had to be taken and these fragments had to be segregated, labeled, and cataloged, which caused further delays in the identification process.

With the readily accessible and available X-ray security screening systems, it was suggested that this equipment be utilized at a temporary morgue site in the primary identification process. These units can be found at airports, government buildings, courthouses, and many commercial buildings. They can be transported easily to a temporary morgue site and can be a valuable adjunct to rapid recognition of remains.

The following study is to compare the efficiency of a manual examination of a body bag to that of a scanner.

Manual Search

Eight "body bags" were prepared with approximately 10 to 15 lb of fresh sheep and pig tissue, which included pig jaws, a pig femur, and a scapula to simulate fragmented human body tissue. Dental specimens, such as individual human teeth (both with and without restorations), bridgework, acrylic full and partial dentures, metal partial dentures, both metallic and nonmetallic fragments, and a wedding ring were placed in red bags to simulate the debris that would be found at a site similar to the U.S. Air Flight 427 crash site.

Members of the Pennsylvania Dental Identification Team (PADIT) were divided into four teams. Each team had a Locator and a Recorder/Timer. The time noted was that time needed for each team to feel confident that it had found all the dental and foreign material in the bag. Each team manually examined two bags. The teams noted as many dental, metallic, and nonmetallic objects as they could recover. All objects were described and times were recorded. The manual examinations of the body bags by experienced forensic odontologists took from 5 to 11 min. See Table 1 for the results of the four teams.

X-Ray Security Screening System Search

The EG&G Astrophysics Linescan Unit, a security scanning system, which we used for our study can be found at airports, embassies, government buildings, courthouses, mailrooms, nuclear plants, and other commercial buildings. They are compact, which allows screening where space may be limited. They operate on either 105 to 125 VAC or 210 to 250 VAC. The X-ray voltage is 160 KVP. The units weigh 1350 lb and most are mounted on wheels.

These Linescan scanners have extended capabilities. In addition to the standard black and white image, they can display a color im-

¹ Chief Deputy Coroner for Chester County, Pennsylvania, 401 Campwood Road, Phoenixville, PA.

² Assistant forensic odontologist, Philadelphia Medical Examiner Office, 5 Cherry Blossom Drive, Churchville, PA.

* An oral presentation of this paper was made at the 51st Annual Meeting of the American Academy of Forensic Sciences, February 1999, Orlando, FL.

Received 16 June 2000; and in revised form 29 Jan. 2001 and 26 March 2001; accepted 26 March 2001.

TABLE 1—*Pennsylvania Dental Identification team manual search.*

Bag No.	Total Search Time	Specimens Present	Specimens Recovered
1	10 min	2 molars (max) 1 molar (mand) 3 bicuspid 1 incisor	2 molars (max) 1 molar (mand) 3 bicuspid 1 incisor
2	9 min	Denture fragment Premolar denture fragment, Maryland bridge #30, cantilever bridge-molar/premolar Mandible with 17, 21, 23, 26, 27, 30	Denture fragment Premolar denture fragment, Maryland bridge #30, cantilever bridge-molar/premolar Mandible with 17, 21, 23, 26, 27, 30
3	7 min	Max partial denture, central (max), laterals (max), bicuspid crown, lateral crown with post	Max partial denture, central (max), laterals (max), bicuspid crown, lateral crown with post
4	9 min	Maxillary partial denture with metal clasps, mandibular molar, cantilever bridge with bonded retainer, left condyle with #18, mandibular anterior tooth	Maxillary partial denture with metal clasps, mandibular molar, cantilever bridge with bonded retainer, left condyle with #18, mandibular anterior tooth
5	5 min	Canine, denture fragment with 9, 10, 11, left mandible fragment with #18, #19, #20, #21, maxillary partial with #7 & #10	Canine, denture fragment with 9, 10, 11, left mandible fragment with #18, #19, #20, #21, maxillary partial with #7 & #10
6	11 min	Mandibular bridge, cast crown, acrylic partial denture	Mandibular bridge, cast crown, acrylic partial denture
7	5 min	No dental remains	No dental remains
8	8 min	Denture fragment with no teeth, maxillary left fragment with 13, 14, 15, maxillary bridge 6, 7, 8, 9 with 3 posts, mandibular molar, mandibular fragment with #18 and impacted #17, gold puzzle ring, maxillary fragment with #1, 2, 3, mandibular canine	Denture fragment with no teeth, maxillary left fragment with 13, 14, 15, maxillary bridge 6, 7, 8, 9 with 3 posts, mandibular molar, mandibular fragment with #18 and impacted #17, gold puzzle ring, maxillary fragment with #1, 2, 3, mandibular canine

age in which organic material such as bone appears orange/brown, inorganic materials such as plastic or acrylic appliances appear blue, and metallic objects such as dental restorations, crowns, and bridges appear green. In addition, the black and white image can be reversed to present the images that are familiar to medical or dental personnel.

The black and white images can be made lighter or darker to enhance the image. The color display can be used to filter out part of the image; this is termed organic stripping. There is also a feature called pseudo-color, which uses a different color for each X-ray density to enhance parts of the image (see Fig. 1).

The image is divided into nine regions. Linescan can magnify each segment up to four times. A hardcopy can be made on some units for future reference.

Method

A simulated "body bag #1" was prepared containing approximately 10 to 15 lb of fresh sheep and pig entrails including a pig jaw with teeth, femur, and scapula to simulate human tissue. This bag was placed on the Linescan unit rollers and viewed on the scanner screen. The pig jaw with teeth, femur, and scapula were located rapidly and without difficulty. The bag was removed; the bones were repositioned in the bag and again processed through the unit to be viewed. All bones were easily located. This was done a third time with the same encouraging results; all specimens were easily distinguished (Fig. 2).

A second body bag (#2) was prepared. Into this bag a human maxilla and mandible containing teeth with restorations, loose teeth both with and without restorations, an acrylic full denture, acrylic partial denture, a metal partial denture, a small plastic pencil sharpener in the shape of a toy gun, a small metal ball, 3/4 in. diameter, and a metal paper clip was placed into the Linescan unit. All items were easily distinguished.

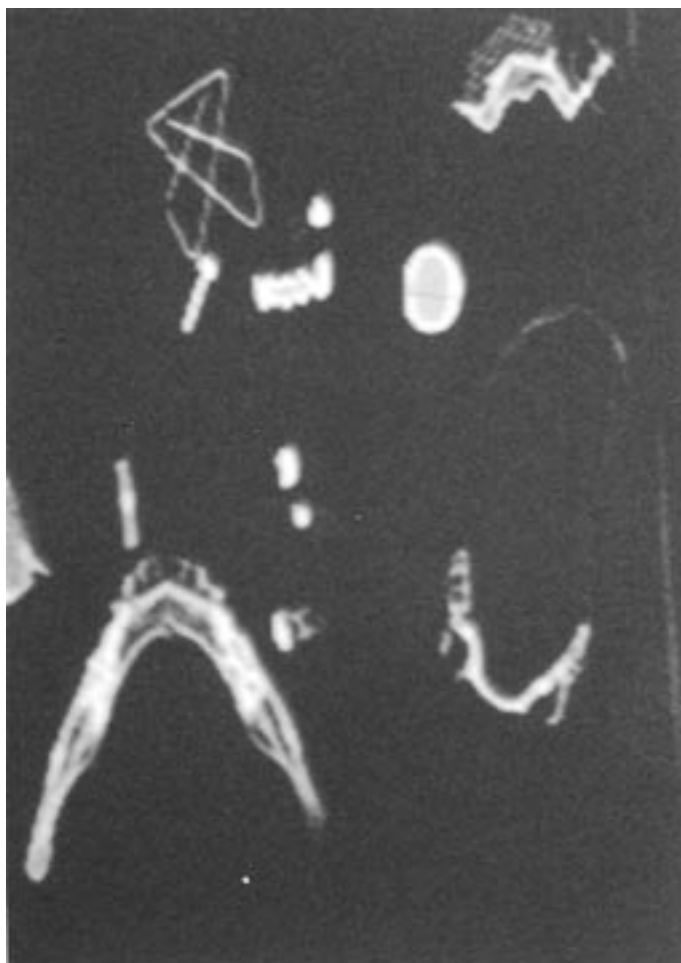FIG. 1—*Simulated bag.*



FIG. 2—First bag with jaws.

The last body bag was made up “body bag #3”; this contained all the items from Bags 1 and 2. This is to simulate a body bag with commingled remains, which might be found at a mass disaster site. All the options on the scanner were utilized and all pig and human dental objects and other foreign objects were quickly and easily identified (Fig. 3).

On a close-up view of teeth, one could observe a two-surface metal restoration (Fig. 4).

Results

The utilization of an X-ray security screening system at a mass disaster site to scan body bags that contain fragmented and commingled remains can facilitate a rapid identification of victims. The results garnered by the above study of scanning of simulated body bags containing pig tissue, human tissue, teeth with and without dental restorations, prosthetic appliances, and foreign objects can

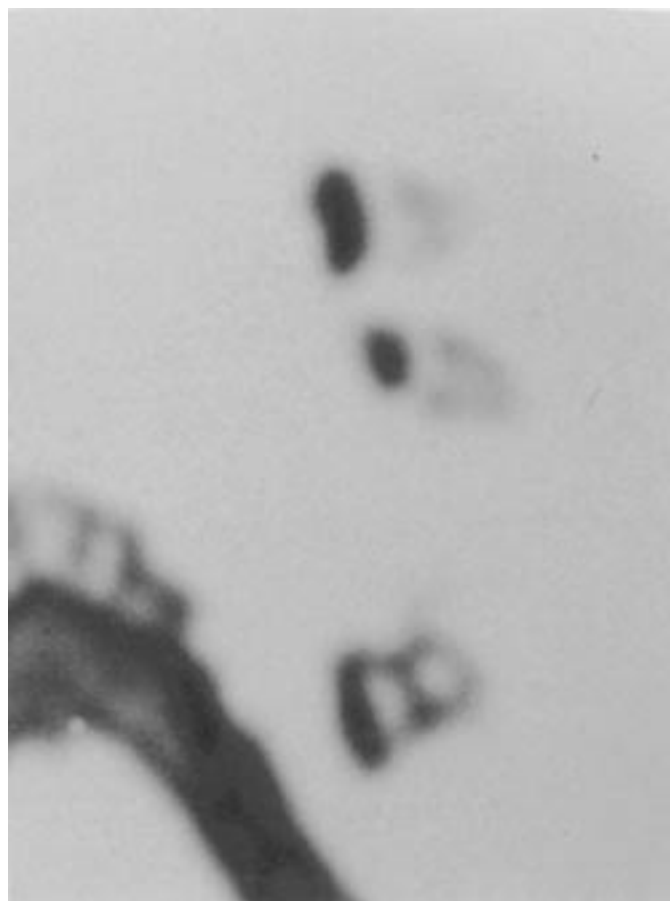


FIG. 4—Close-up view teeth.

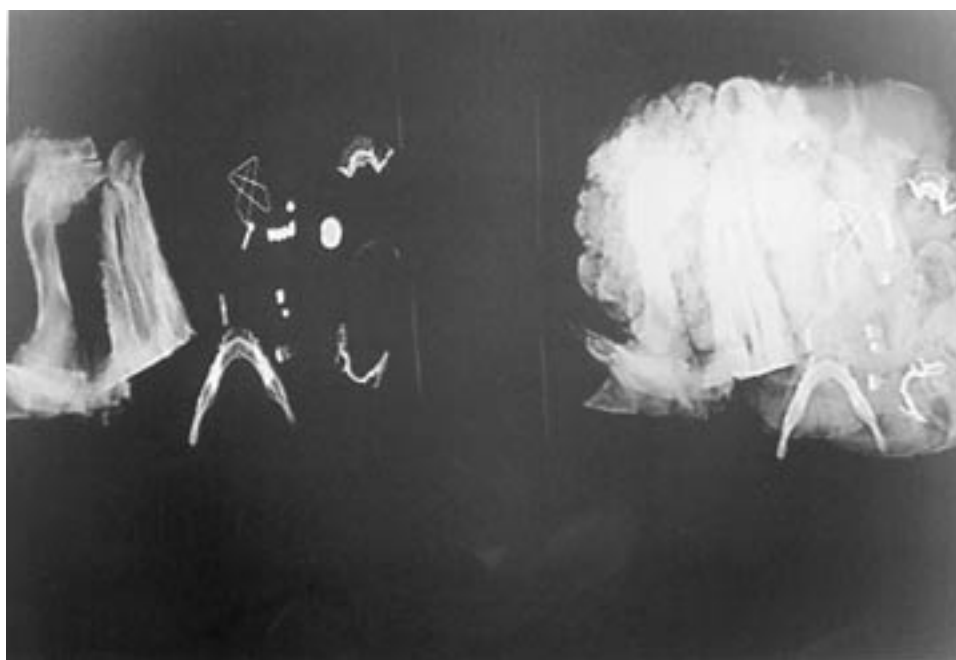


FIG. 3—Left view, all study materials not covered by entrails; right view, all study materials covered by entrails.

be readily discernible and identifiable when viewed by the scanning units.

Conclusions

The X-ray Security Scanning System is a rapid and efficient method for scanning body bags at a mass disaster site. The availability of these units and the ease of operation make it far superior to the use of X-rays which are taken at the site and then have be processed at a remote location. After all dental remains are obtained, trained forensic odontologists must be utilized to do proper dental comparisons and provide identifications. The scanners will help segregate and identify questionable objects, but a manual examination by a trained forensic odontologist is still needed for a definitive identification.

Acknowledgments

The authors would like to acknowledge the PADIT team: Dr. Richard Scanlon, PADIT, team leader; Dr. William Yeomans, PADIT, director; Dr. Haskell Askin; Dr. Bernard Wujcik; Dr. Roger Rothenberger, Coroner, Chester County, PA; Nancy Cheyne, assistant to the coroner; Chester County Court House, Office of the Sheriff; Kolb Brothers Butchers; and computer assistance, Bruce Goodman and Jeffrey Goodman.

Additional information and reprint requests:
Dr. Norman R. Goodman
401 Campwood Rd
Phoenixville, PA